

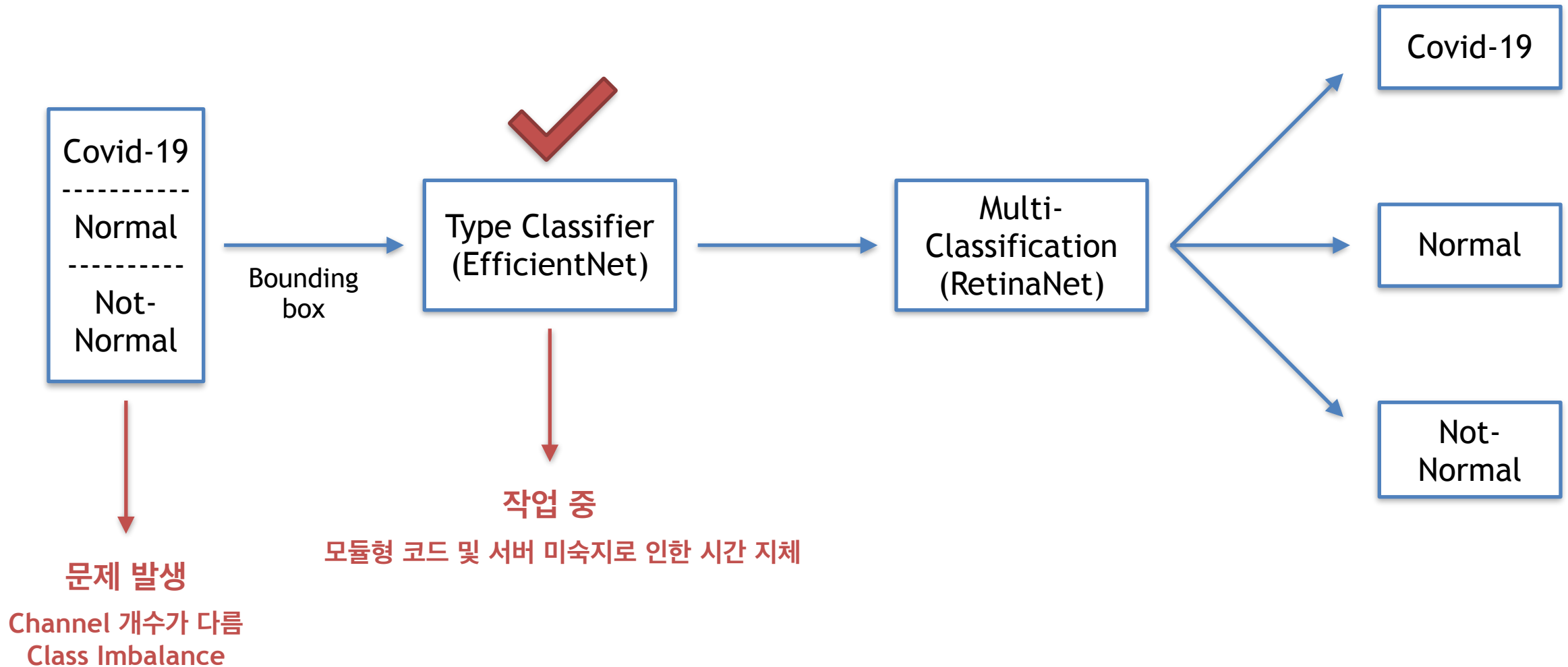
한국인공지능연구소 8기

Eagle Eye Lab

3월 13일

Covid-19 Detection on Chest X-Rays
with Deep Learning

주간 보고



A close-up photograph of a silver stethoscope with blue tubing resting on a medical chart. The chart has a grid and some text, including 'Datum:' and 'Vrijeme:'. A large, dark teal circular overlay is positioned on the right side of the image, containing the text 'THANK YOU' in white, bold, sans-serif capital letters. The background is slightly blurred, showing more of the medical chart and the stethoscope's tubing.

THANK
YOU